

Extracanal Invasive Resorption: A Clinical Perspective

In recent years, extracanal invasive resorption has become accepted as a separate and distinct form of dental resorption. There continues to be some confusion in the literature, however, as this particular resorptive process has been referred to by many names and has often been confused with more easily diagnosed and more easily managed resorptive lesions. The term extracanal invasive resorption appears to be the more widely used identification in the literature,¹⁻⁵ although cervical resorption is the preferred term in the *Glossary of Endodontic Terms*.⁶ The purpose of this article is to clarify the radiographic identification and clinical interpretation of extracanal invasive resorption.

DIAGNOSIS AND CLINICAL INTERPRETATION

The extracanal invasive resorptive process begins in the gingival attachment or periodontal ligament. In a broader sense, therefore, it can be considered a form of external resorption. A relatively small resorption hole is developed in the periphery of the root

during the initial resorptive process and it extends through the cementum into the dentin (Figure 1A). When the soft tissue is removed from an extracted tooth, the resorption holes have an appearance similar to small worm holes on the surface of an apple. A number of small resorption holes may be associated with a single extracanal invasive resorption lesion, and often occur on different surfaces of the tooth (Figure 1B). This observation is of obvious importance in treatment planning considerations. It is through these resorption holes that small blood vessels from the periodontal ligament or the attachment maintain or feed the resorptive tissue inside the root.

The resorptive process extends as finger-like projections into the dentin. As the resorbed holes in the external surface and the associated extensions into the peripheral dentin are relatively small in diameter, it is rare that this aspect of the resorbed lesion can be identified on radiographs. Within the body of dentin the resorptive process tends to extend in a vertical direction, apically, coronally,

Gerald W. Harrington, DDS, MSD
Professor Emeritus

David R. Steiner, DDS, MSD
Affiliate Professor

Tiina Oviir, DDS
Clinical Associate Professor

Department of Endodontics
University of Washington
School of Dentistry
Seattle, Washington

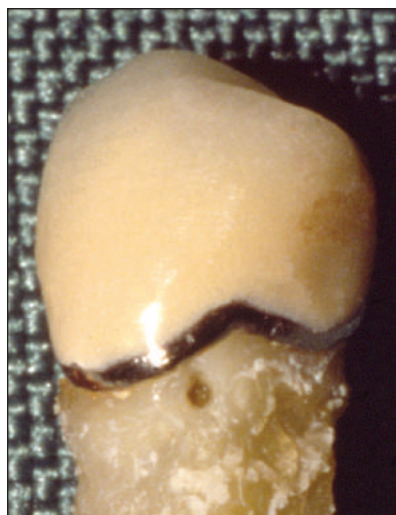

Figure 1A A small resorption hole can be identified at the attachment level at the buccal line angle of this mandibular premolar.

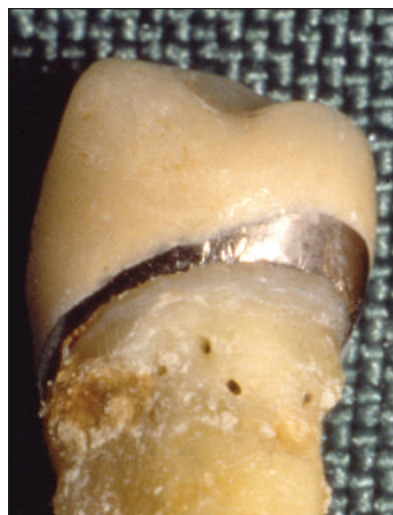

Figure 1B If the premolar is rotated, four resorption holes can be seen on the lingual and proximal surfaces.

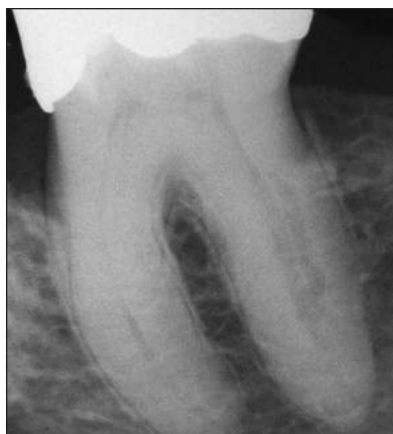

Figure 2A An extracanal invasive resorption can be identified distal to the canal space in the distal root of this mandibular molar.

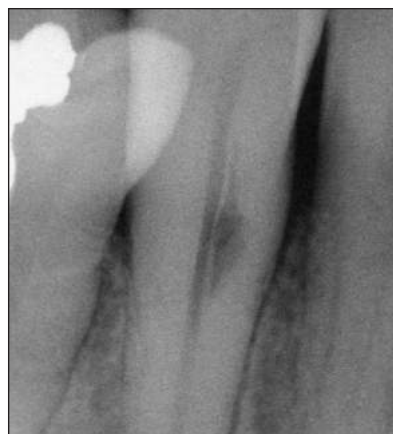

Figure 2B An extracanal invasive resorption can be identified lateral to but parallel with the canal space. No radiographic evidence can be identified of a resorption hole at the root surface or the resorbed pathway from the periphery to the main focus of resorption. Small radiolucent projections (“spider legs”) extend from the main focus of the resorption.

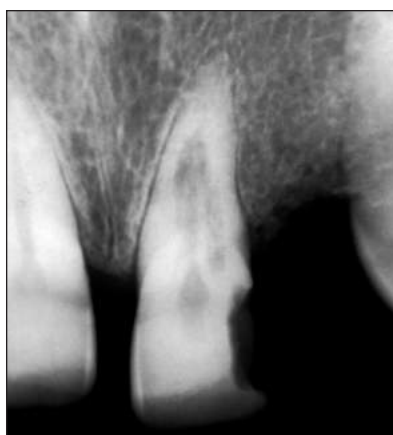

Figure 3A Radiograph of a maxillary central incisor with an extracanal invasive resorption lesion.

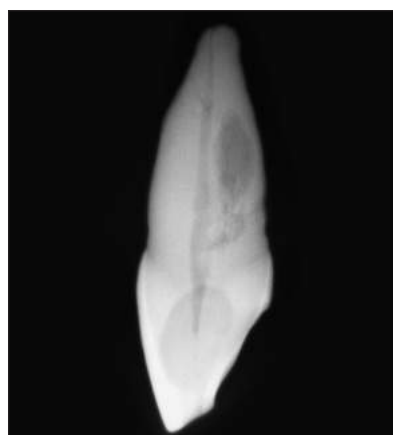

Figure 3B A proximal radiograph of the extracted tooth demonstrates a resorptive lesion palatal to the intact root canal. Figure 3A demonstrates that the coronal extent of the resorption is distal to the root canal.

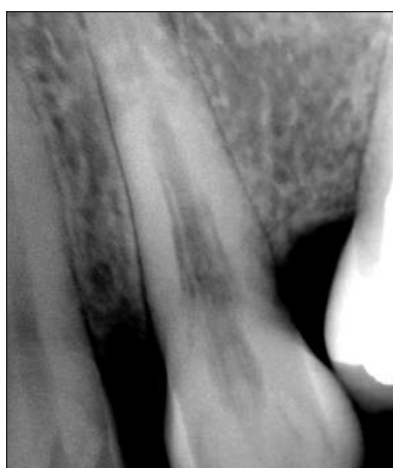

Figure 4 The extracanal invasive resorptive lesion in this maxillary cuspid has the radiographic appearance of radiolucent lines running parallel to the canal space on both the mesial and distal.

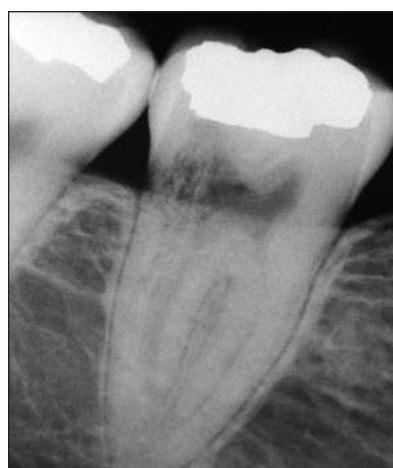

Figure 5 The extracanal invasive resorption in this mandibular molar has a mottled appearance.

or both. The resorbed area within the body of the dentin must commonly be quite advanced before it can be recognized on radiographs (Figure 2A and Figure 2B). At this stage in the development of extracanal invasive resorption, the lesion commonly has minute radiolucent projections extending from the main focus of the resorption (Figure 2B). These projections may have the appearance of small “spider legs.” Extracanal invasive resorption, therefore, can first be recognized when the resorption has developed sufficiently within the body of dentin between the root canal and the external surface of the tooth. During this phase, there is seldom a communication with the root canal space or the pulp chamber (Figure 3A and Figure 3B). The resorption tends to extend within the body of the dentin around the canal space. The radiolucency of the resorption often appears to parallel the canal space (Figure 4).

Extracanal invasive resorption at this stage may also assume a mottled appearance, somewhat similar in appearance to a trabecular pattern (Figure 5). It is quite easy to recognize the difference in the radiolucent patterns between the resorbed areas in Figure 5 and Figure 2B. However, it is not known whether the differing patterns may suggest a difference in clinical significance or prognosis. For the present, the two differing radiolucent patterns must simply be considered evidence of extracanal invasive resorption.

When an extracanal invasive resorption has progressed to a size that can be identified on a radiograph, its future course may proceed in one of three ways: (1) it may continue its invasive process and destroy a large part of the root of the tooth, (2) it may become quiescent and not change in size or contour for many years, or (3) it may seem to reduce in size with time or may even seem to disappear.

If the resorptive area continues to increase in size, the rate at which extracanal invasive resorption progresses is an unknown. It is likely that there may be periods of diminished activity as well as periods of markedly aggressive activity. It has been observed that this type of resorption can remove dentin very

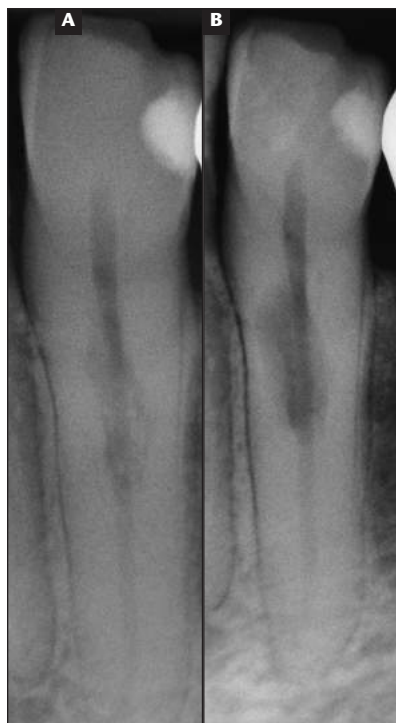

Figure 6A Extracanal invasive resorption can be identified in the radiograph of this mandibular cuspid. A previous radiograph demonstrated little or no change in the radiographic appearance over a period of 5 years.

Figure 6B This radiograph was taken 4 months after the radiograph in Figure 6A and demonstrates a large resorptive defect.

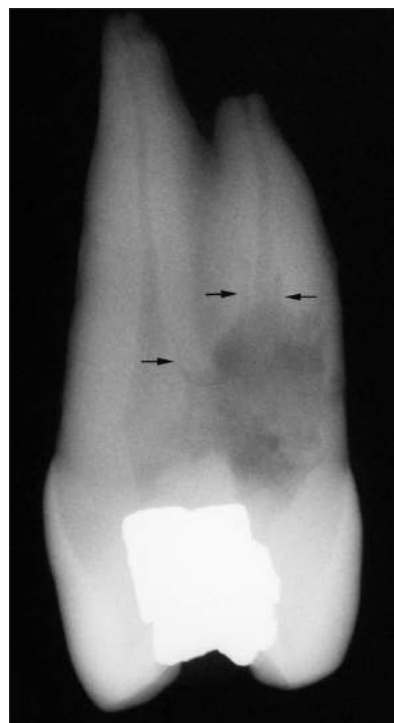

Figure 7 A proximal radiograph of this extracted tooth demonstrates a very large resorptive lesion that has resorbed a large part of the wall of the pulp chamber and palatal root canal. "Spider legs" are marked by arrows. The root of the extracted tooth appeared to be intact. A small resorption hole could be identified on the palatal surface of the root.

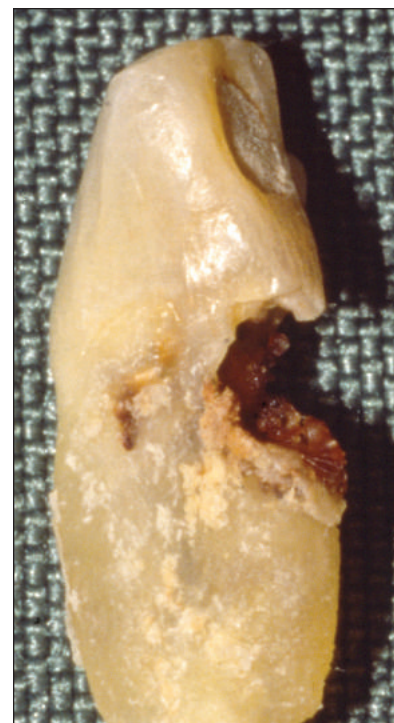


Figure 8 This extracted mandibular incisor demonstrates an extensive extracanal invasive resorption that has hollowed out the lingual surface.

rapidly and result in a very large resorptive defect within a short period of time (Figure 6A and Figure 6B). In more progressive lesions, the walls of the chamber and canal can be destroyed and the pulp tissue in the area of resorption replaced by tissues of the resorptive lesion (Figure 7). In an advanced stage, the external aspect of the root may become extensively resorbed and result in a large hollowed-out defect in the external surface (Figure 8).

In some cases, an extracanal invasive resorption may not change much in size or contour over many years (Figure 9A and Figure 9B). In this example, there is a 10-year time span. From previous radiographs, this resorptive process occurred sometime within a 2-year period prior to the radiograph for Figure 9A. Therefore, this resorption developed fairly rapidly sometime within a 2-year period, and then became relatively quiescent over the next 10 years. The problem with observations such as this, ie, of little or no change in the size or contour of a radiolucent resorbed lesion over

an extended period of time, is that it is not predictive of what the future course may be for this type of resorptive lesion. In the case of the mandibular molar in Figure 9B, we know that there have been relatively minor radiographic changes over a 10-year period, but we are not able to predict with any certainty what will happen at 12 years, 15 years, or 20 years. It is absolutely unpredictable. There may be little or no change in the radiographic appearance, the radiolucency may markedly increase in size, or the radiolucent appearance of the lesion may disappear. While a discussion of treatment options is beyond the scope of this article, the question of prognosis must be raised. With whatever treatment that might have been considered for this molar in Figure 9A, is it predictable that the treated tooth would have survived for 10 years? In this case, it did survive with no treatment. Such outcomes do occur, but are not predictable.

The third and final possible outcome of an extracanal invasive resorption that is identified fairly early in the resorptive

In some cases, an extracanal invasive resorption may not change much in size or contour over many years... we are not able to predict with any certainty what will happen at 12 years, 15 years, or 20 years.

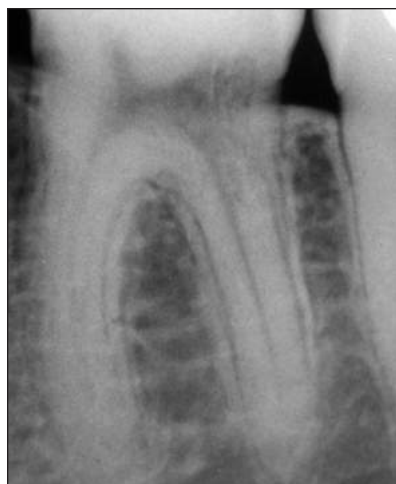

Figure 9A Extracanal invasive resorption in the distal of a mandibular molar. A radiograph taken 2 years prior to this radiograph showed no evidence of resorption.

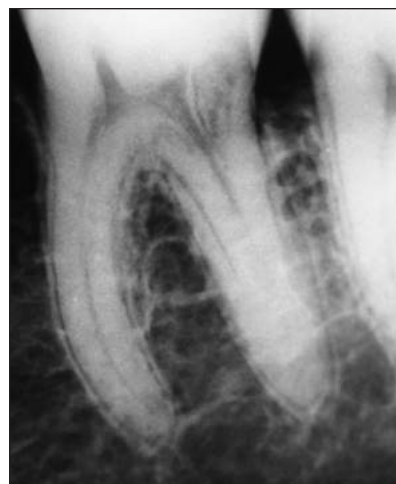

Figure 9B A radiograph taken 10 years after Figure 9A.

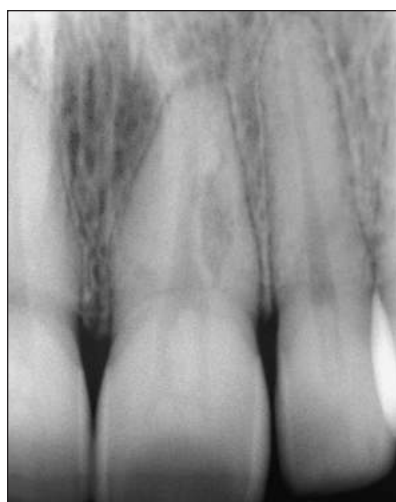

Figure 10A Extracanal invasive resorption in the root of a maxillary central incisor. "Spider legs" can be identified.

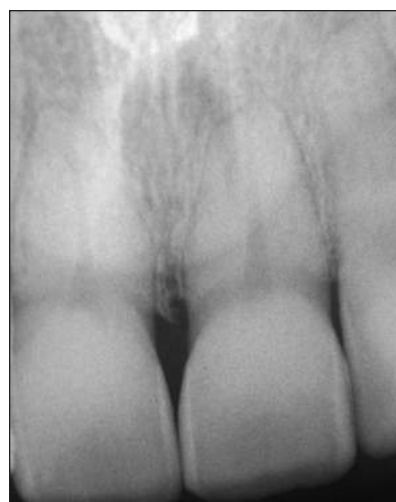

Figure 10B A radiograph taken 21 years after Figure 10A shows no evidence of resorption.

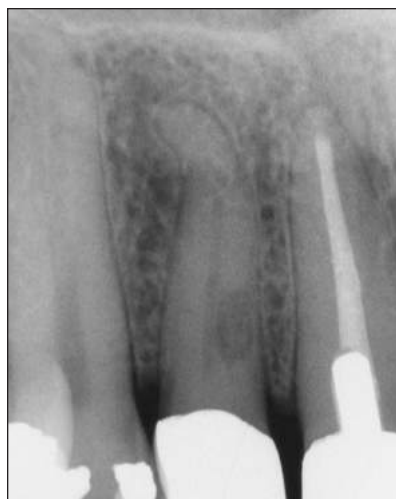

Figure 10C Extracanal invasive resorption in a maxillary lateral incisor.

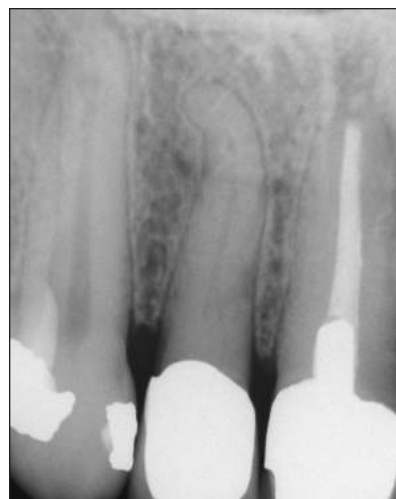

Figure 10D A radiograph taken 7 1/2 years later shows little evidence of the original resorption.

process is that the radiolucent lesion may appear to resolve (Figure 10A through Figure 10D). Commonly, there is radiographic evidence of a gradual decrease in the size of the resorption radiolucency over a number of years until there is an appearance of no remaining radiolucent lesion or only the suggestion of a small remnant. As this may be viewed as an unexpected result, the question may be raised as to how it could even occur. Clearly, the cellular elements in the resorptive tissue are not only capable of resorbing cementum and dentin but are also capable of laying down new calcified tissue within the area of resorption. In some cases, the tissue may lay down irregular segments of new calcified tissue within the resorption and result in a radiographic appearance suggestive of a trabecular pattern. In other circumstances, it may lay down new calcified tissue on the resorbed dentin surface, gradually reducing the size of the radiolucent area until it cannot be identified on radiographs. It is most likely that there is some soft tissue remnant but it would have to be of small caliber. Whether or not an extracanal invasive resorptive lesion which appears to have resolved may reverse the process with a recurrence of the resorption is unknown.

Occasionally in a tooth with a horizontal root fracture, the coronal segment of the tooth may subsequently develop a radiographic appearance similar to extracanal invasive resorption.^{7,8}

Andreasen refers to this as internal tunneling resorption. Similar radiographic appearances may also occasionally occur after other kinds of dental trauma that are not associated with root fractures, particularly extrusive luxations.⁹ When observed, it appears that no treatment is indicated. Andreasen presents evidence that the radiographic appearance similar to that of extracanal invasive resorption appears to return to a radiographic image that is within normal limits over some period of years.

It should also be noted that a patient with an identified extracanal invasive resorption may have more than one tooth involved with a resorptive process. The incidence of multiple teeth being involved appears to be high enough to warrant consideration for a

The entire blood supply to the extracanal invasive resorptive lesion must be severed. If it is not, it is extremely likely that the resorptive process will continue...

full-mouth radiographic survey when a single extracanal invasive resorption has been identified. There seems to be no consistent pattern when multiple teeth are involved. The authors have had such disparate combinations as all four cuspids with extracanal invasive resorption in one patient and five consecutive teeth, mandibular left central incisor to right first bicuspid, in another.

EXTRACANAL INVASIVE RESORPTION VS EXTERNAL INFLAMMATORY RESORPTION

While a discussion of terminology related to resorption may seem academic, a precise definition is critical to make an accurate diagnosis, determine an appropriate prognosis, and apply proper treatment.

As noted in the introduction, the form of resorption described in this paper has been referred to by many names.^{3,10} At present, the more commonly used names are extracanal invasive resorption,¹⁻⁵ cervical resorption,⁶ and invasive cervical resorption.¹⁰⁻¹² The authors believe that in the nomenclature of dental resorptions, extracanal invasive resorption provides a more accurate description of the lesions described in this article. Many of these lesions occur in the cervical area of the tooth, but many also occur at various levels farther apical in the root. The resorptive lesions in Figure 2A and Figure 2B are examples of extracanal invasive resorption lesions that occur apical to the cervical part of the root. Resorptions such as these do not quite fit into a cervical resorption classification.

The authors also believe that use of the term extracanal invasive resorption should be more restrictive and more precisely defined. The resorptive lesions described by Heithersay and by Frank include what historically have been referred to as external resorption of an inflammatory origin. As an example,

Heithersay lists resorption related to intracoronary bleaching of endodontically treated teeth as one of the three most frequent causes of invasive cervical resorption.¹⁰ In his clinical classification, resorptions caused by bleaching would be listed as Class I or Class II invasive cervical resorptions. Resorptions related to bleaching in Frank's extracanal invasive resorption categories would be referred to as supraosseous or crestal.³ The radiographic appearance of the many bleaching resorption cases reported in the literature since 1979, however, do not resemble in any manner the radiographic appearances described in this article. The radiolucent lesions associated with bleaching resorption are similar in radiographic appearance to inflammatory resorption related to displaced or avulsed teeth. Andreasen describes inflammatory resorption as "characterized by radiolucent bowl-shaped cavitations along the root surface."¹³ Resorptions related to bleaching are inflammatory in origin, occur at the level of the gingival attachment or crestal bone, and are identified by radiolucent lesions similar to inflammatory resorption (Figure 11). Not only is the radiographic appearance of an external inflammatory resorption different than the radiographic appearances of extracanal invasive resorption lesions, but the clinical appearance of the lesions after being surgically exposed is also completely different and the lesions differ markedly in their complexity. Radiographically and clinically they are, therefore, distinctly separate kinds of lesions.

If the resorptive lesions related to bleaching, as well as other resorptive lesions more appropriately described as external resorption of an inflammatory origin, are separated from the types of lesions described in this article, then it can be stated that the prognosis for the clinical management of external inflammatory resorption is commonly quite good, while the prognosis for the

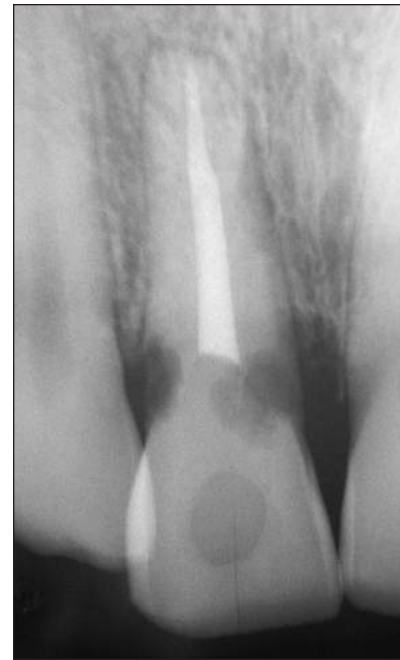

Figure 11 External resorption related to bleaching. Radiolucent lesions are evident on both the distal and the mesio-palatal surfaces in the cervical area of the root.

lesions described in this article is generally rather poor. It is, therefore, critical to the interest of our patients to recognize extracanal invasive resorption as a separate and distinct form of resorption and to be able to distinguish it from other forms of resorption.

DIFFERENTIATION

The radiographic characteristics of extracanal invasive resorption (a vertical contour, a radiolucency parallel to an intact root canal space, "spider legs" extending from the main focus of the resorption, a mottled appearance) make positive identification of this form of resorption possible, and distinguish it from other types of resorption. The typical radiographic appearance of replacement resorption or of inflammatory resorption related to displaced or avulsed teeth is an easy discrimination. Internal resorption can also be readily identified.

The circumstances that make it somewhat difficult to make an accurate discrimination is the case of an external inflammatory resorption in the cervical area as opposed to an advanced-stage extracanal invasive resorption in the same area which has produced a large hollowed-out area in the external surface. It is of marked clinical importance

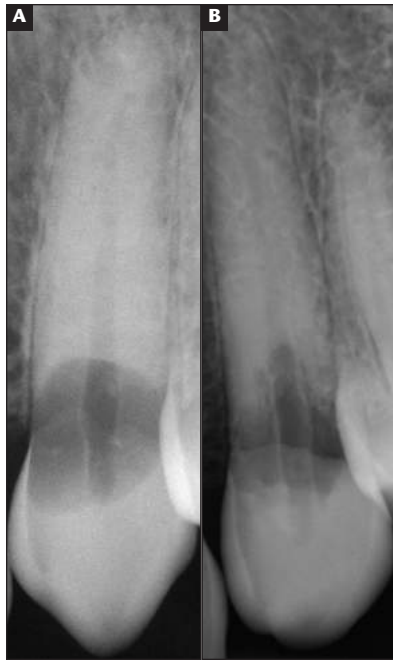

Figure 12A This very large external inflammatory resorption in the cervical area has a rather smooth peripheral outline. The outline of the root canal space can clearly be identified through the radiolucency of the resorptive lesion.

Figure 12B This very large extracanal invasive resorption in the cervical area has a markedly ragged peripheral outline. Examination of the radiograph with a magnifying glass reveals several "spider legs." Again, the outline of the root canal space can clearly be identified through the radiolucency of the resorptive lesion.

to make the distinction between the two as the prognosis for effectively managing an external resorption of moderate size is extremely good, while the prognosis for an extracanal invasive resorption of similar size is always questionable at best. Both have wide-mouthed openings on the resorbed surface which can be identified with a G-2 explorer. The radiographic appearance, however, is often distinctive. In the case of external resorption, the outline of the radiolucent lesion may be relatively smooth (Figure 12A); while in extracanal invasive resorption it is commonly rather ragged in contour (Figure 12B). In some cases, however, the radiographic discrimination between the two lesions may not be entirely straightforward. As a surgical repair is required for both lesions, identification of tiny bleeding points within the walls of the denuded hard tissue lesion becomes critical in discriminating between the two. In the case of external resorption of an inflammatory nature, the inflammatory tissue

tends to peel out of the resorbed area with relative ease, leaving a relatively smooth internal wall. If a bleeding point is identified, it is usually centered over the canal and, if so, a perforation into the root canal may be suspected. In contrast, the surgically exposed internal wall of an extracanal invasive resorption lesion is commonly somewhat ragged in appearance.

Identification of bleeding points within the wall, not associated with perforation into the canal or chamber, is positive identification of extracanal invasive resorption. The bleeding points are usually very small in caliber and are peripheral in position to the canal. The bleeding points represent internal ramifications of the blood supply entering through additional resorption holes somewhere on the intact external root surface. Location of the source or sources of this blood supply is of paramount importance if the surgical repair is to be successful. The entire blood supply to the extracanal invasive resorptive lesion must be severed. If it is not, it is extremely likely that the resorptive process will continue, and very likely that it will progress at a very rapid rate.

Extracanal invasive resorption must also be recognized as being a separate and distinct form of resorption from two other resorptions that occur in the cervical area of the tooth. As previously noted, external resorption associated with intracoronary bleaching always occurs in the cervical area,¹⁴ and physiologic or pressure resorption, which may be present after the eruption of an adjacent tooth, often occurs in the coronal third of the root.¹⁵ Since each has very distinctive resorption appearances on radiographs, it is not likely either would be confused with extracanal invasive resorption.

CONCLUSION

Extracanal invasive resorption has the following characteristics:

- It commonly has a vertical contour rather than horizontal.
- It may appear to lie parallel to the canal space.
- It usually has minute radiolucent projections extending from the main focus of resorption ("spider legs").

- It always has a small communication with the periodontal ligament or attachment.
- There are most often multiple communications with the periodontal ligament or attachment.
- There may or may not be a communication with the pulp chamber or canal.
- The radiographic appearance of the resorption may change with time: It may get more radiolucent (involving a larger area of the tooth), or it may get less radiolucent (more radiopaque). Repair takes place with a calcified tissue.
- It may have a mottled appearance (a mixture of small radiopaque and radiolucent areas).
- There may be more than one tooth involved with resorption.

REFERENCES

1. Frank AL, Simon JHS, Abou-Rass M, Glick DH. *Clinical and Surgical Endodontics, Concepts in Practice*. Philadelphia: JB Lippincott. 1983; 147-151.
2. Frank AL, Bakland LK. Nonendodontic therapy for supraosseous extracanal invasive resorption. *J Endod*. 1987;13:348-355.
3. Frank AL. Extracanal invasive resorption: an update. *Compend Contin Educ Dent*. 1995; 16:250-262.
4. Benenati FW. Extracanal invasive root resorption: a perplexing oddity. *Gen Dent*. 2002; 50:70-71.
5. Ingle JJ, Heithersay GS, Hartwell GR, et al. Endodontic diagnostic procedures. In: Ingle JJ, Bakland LK, eds. *Endodontics*. 5th ed. Hamilton, Ont: BC Decker Inc. 2002:232-238.
6. *Glossary of Endodontic Terms*. 7th ed. Chicago: American Association of Endodontists. 2003:43.
7. Andreasen FM, Andreasen JO. Resorption and mineralization processes following root fracture of permanent incisors. *Endod Dent Traumatol*. 1988;4:202-214.
8. Andreasen JO, Andreasen FM. *Textbook and Color Atlas of Traumatic Injuries to the Teeth*. 3rd ed. Munksgaard and Mosby. Copenhagen and St. Louis. 1994:287-288.
9. Andreasen JO, Andreasen FM. *Textbook and Color Atlas of Traumatic Injuries to the Teeth*. 3rd ed. Munksgaard and Mosby. Copenhagen and St. Louis. 1994:209, 372.
10. Heithersay GS. Invasive cervical resorption. *Endodontic Topics*. 2004;7:73-92.
11. Heithersay GS. Clinical, radiologic, and histopathologic features of invasive cervical resorption. *Quintessence Int*. 1999;30:27-37.
12. Heithersay GS. Invasive cervical resorption: an analysis of potential predisposing factors. *Quintessence Int*. 1999;30:83-95.
13. Andreasen JO, Andreasen FM. *Textbook and Color Atlas of Traumatic Injuries to the Teeth*. 3rd ed. Munksgaard and Mosby. Copenhagen and St. Louis. 1994:398.
14. Harrington GW, Natkin E. External resorption associated with bleaching of pulpless teeth. *J Endod*. 1979;5:344-348.
15. Worth HM. *Principles and practice of oral radiologic interpretation*. Chicago: Year Book Medical Publishers, Inc. 1963:167-169.